

Case report

Open Access

Histopathological changes in the human larynx following expanded polytetrafluoroethylene (Gore-Tex®) implantation

K Rajkumar*¹, HS Khalil¹, M Elloy², E Sheffield³ and DL Baldwin²

Address: ¹Departments of Otolaryngology/Head and Neck Surgery, Derriford Hospital, Plymouth, UK, ²Departments of Otolaryngology/Head and Neck Surgery, Southmead Hospital, Bristol, UK and ³Department of Pathology, Frenchay Hospital, Bristol, UK

Email: K Rajkumar* - rajnasha@yahoo.co.uk; HS Khalil - hkhalil@breathemail.net; M Elloy - mdelloy@yahoo.com; E Sheffield - edward.sheffield@north-bristol.swest.nhs.uk; DL Baldwin - eva.hicks@north-bristol.swest.nhs.uk

* Corresponding author

Published: 21 January 2005

Received: 20 June 2004

BMC Ear, Nose and Throat Disorders 2005, 5:1 doi:10.1186/1472-6815-5-1

Accepted: 21 January 2005

This article is available from: <http://www.biomedcentral.com/1472-6815/1>

© 2005 Rajkumar et al; licensee BioMed Central Ltd.

This is an Open Access article distributed under the terms of the Creative Commons Attribution License (<http://creativecommons.org/licenses/by/2.0>), which permits unrestricted use, distribution, and reproduction in any medium, provided the original work is properly cited.

Abstract

Background: Expanded polytetrafluoroethylene (e PTFE, Gore-Tex®) has been advocated as an implant material for medialization of the vocal fold. Animal studies involving rabbits and a porcine model have demonstrated host tolerance of the implant. There have been no reports describing the histological changes in a human laryngectomy specimen with a Gore-Tex implant.

Case presentation: The histological findings in a laryngectomy specimen of a patient previously implanted with e PTFE for medialization of a paralyzed vocal fold following excision of a vagal neurofibroma were studied.

Histopathology revealed a mild foreign-body giant cell granulomatous reaction with some associated fibrosis. The granulomatous response was limited to the periphery of the Gore-Tex and although it closely followed the profile of the material it did not encroach into or significantly break up the material. There was no significant neutrophilic or lymphocytic inflammation.

Conclusions: Our findings are consistent with the animal models confirming that Gore-Tex implantation does not result in a significant granulomatous reaction in the human larynx over a 13-month period. Moreover, there is no evidence of resorption or infection. Further, the lack of lymphocytes in association with the granulomas indicates that there is no significant immunological hypersensitivity. Histologically, the slight permeation by connective tissue is similar to that seen in Gore-Tex vascular and cardiac implants. The degree of the slight giant cell response appears to be dependent on the profile of the material; a sharp edge incited more of a response than a flat surface.

Background

Unilateral vocal fold paralysis is symptomatic when it results in failure of the mobile vocal fold to approximate the paralyzed vocal fold during adduction. Despite the lack of movement, the paralyzed vocal fold will often contact the contra lateral mobile vocal fold permitting adequate glottic closure [1].

Medialization laryngoplasty is a common procedure used to restore glottic competence. This procedure was popularized by Ishiki and initially used in patients with vocal fold paralysis. In recent years, the indications for this procedure have expanded to include most forms of glottic incompetence, including the use of bilateral medialization in mobile vocal folds for vocal fold bowing and atrophy [2].

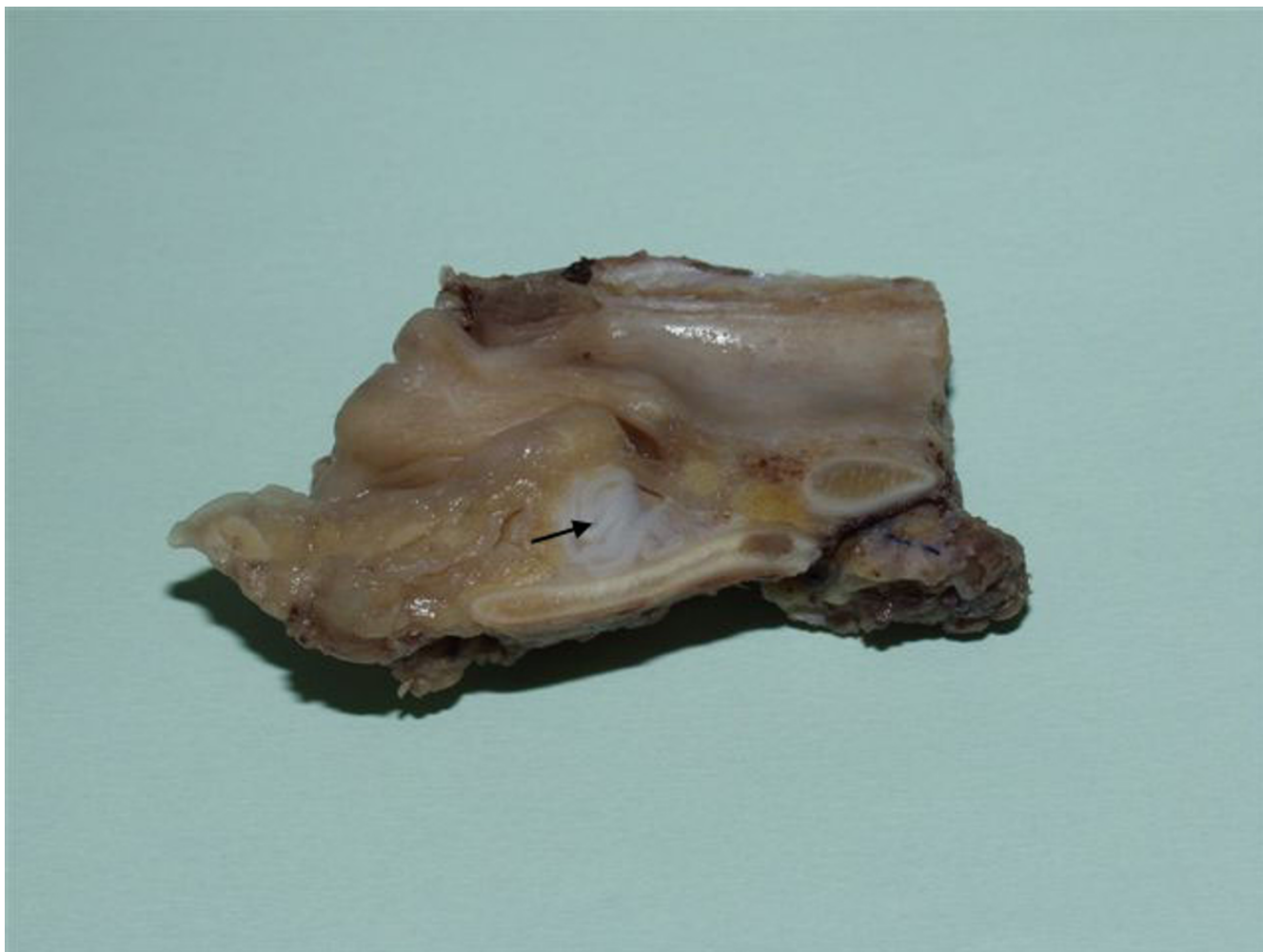

Figure 1
Laryngectomy specimen showing Gore-Tex (arrow) as a pale nodule in the paraglottic space lying beneath an intact mucosa.

Although medialization is now widely accepted, the choice of implant material is still a subject of controversy. The ideal vocal fold injection material would be readily available, have excellent biointegration with no or minimal immunologic response, has an excellent biomechanical in vivo match to the injection site tissues, and is deliverable through a fine-gauge needle. Such a material does not presently exist.

Teflon (Polytetrafluoroethylene) was the first modern material used for vocal fold injection. Long-term results, unfortunately, have shown an unacceptably high rate of granuloma formation associated with Teflon injection. This results in a gradual degradation of the injected material by foreign body giant cells and fibroblastic proliferation in the location of the implant [3]. Autologous tissues

such as fat or fascia are well described. These tissues have the benefit of medializing the vocal fold with minimal tissue reaction [4,5]. Collagen injection has been used with some success, its major drawback is the need for serial injections in some cases [2].

Recently, an expanded polytetrafluoroethylene implant (ePTFE, Gore-Tex®) has been advocated as an implant material for medialization of the vocal fold [6]. This material has been widely used in cardiac- and vascular surgery and soft tissue augmentation with minimal complications [2]. Cashman et al published a histological study of changes in the rabbit larynx in response to Gore-Tex implantation. They found evidence of a foreign body giant cell reaction and a thin rim of fibrous tissue surrounding the implant. Although the fibrous capsule invaginated between the

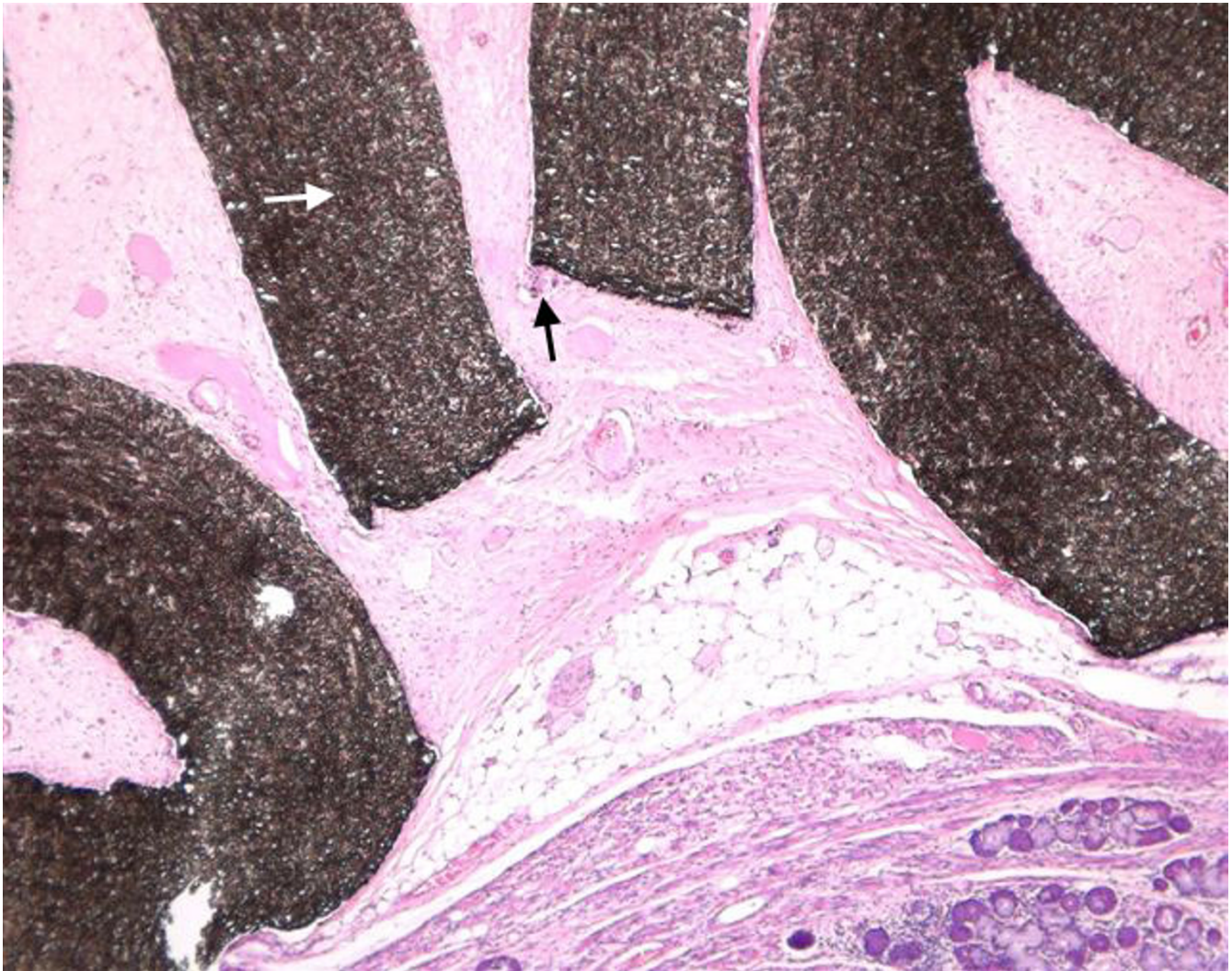


Figure 2

Low power magnification showing broad interlacing bands of Gortex material (white arrow) surrounded by mild foreign-body giant cell granulomatous reaction with some associated fibrosis (black arrow).

folds of the implant, it did not appear to grow into the implant itself. The implant was secure in the soft tissue with no migration or spontaneous extrusion noted [2].

Case presentation

A 64-year-old female patient underwent transcervical excision of a right vagal neurofibroma. This was complicated by right vocal fold paralysis with dysphonia and aspiration. Six months later, the patient underwent fat injection for medialization of the right vocal fold. After an initial improvement, the patient suffered a recurrence of the aspiration, chest infections and dysphonia.

The patient subsequently underwent right medialization using Gore-Tex implant (Gore Thyroplasty Device, Medtronic, Xomed®) with cricothyroid approximation. Videofluoroscopy and Speech assessment confirmed an improvement in aspiration and speech. Six months later, her symptoms recurred with subsequent aspiration pneumonia. A decision was made after lengthy counseling to proceed with a laryngectomy 13 months following the implantation of Gore-Tex. Figure 1 shows the Gore-Tex in the laryngectomy specimen.

Histopathology

Light microscopy revealed a mild foreign-body giant cell granulomatous reaction with some associated fibrosis

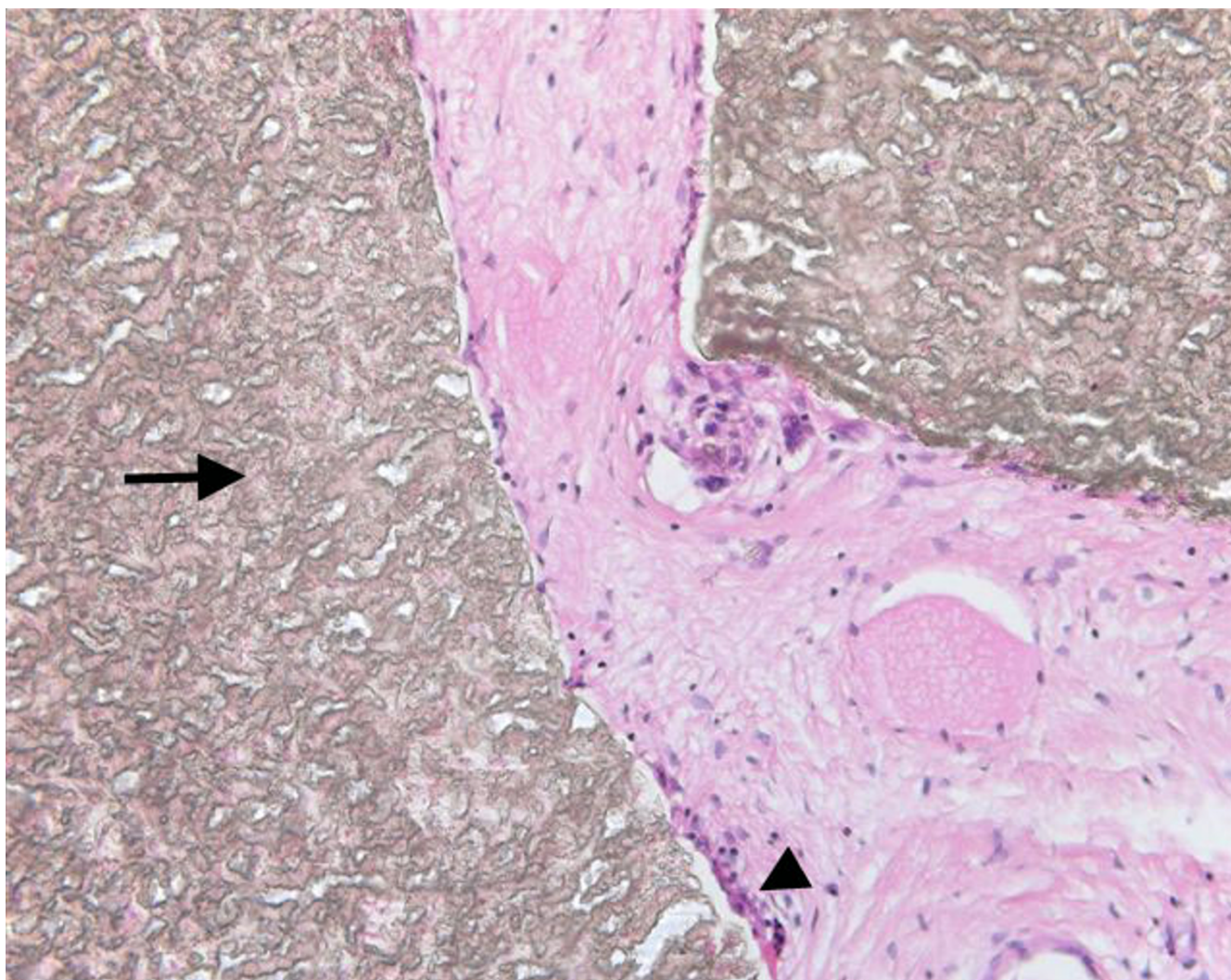


Figure 3

High power magnification showing only a small number of multinucleated foreign-body type macrophage giant cells (arrow-head) associated with the periphery of the Gore-Tex bands (arrow). There is little evidence of breakdown of Gore-Tex.

(Figures 2 and 3). The granulomatous response was limited to the periphery of the Gore-Tex and although it closely followed the profile of the material it did not encroach into or significantly break up the material. However, some fibrosis penetrated a short way into the Gore-Tex in a few areas. The giant cells were present mainly in a multinucleated form. Figure 4 shows the Gore-Tex strip under crossed Polaroids showing birefringence of the implanted material. Birefringent fragments were only very occasionally seen within isolated giant cells. The giant cell response was mainly seen in areas where the end of a Gore-Tex strip formed a sharp corner. In one area a very small focus of metaplastic bone formation was seen.

There was no significant lymphocytic, neutrophilic inflammation or vascular ingrowth.

Discussion

Gore-Tex has been used as an effective implant for medicalization laryngoplasty in the management of paralytic dysphonia and to a lesser extent aspiration [6,7]. Animal studies involving rabbits and a porcine model have demonstrated host tolerance of the implant, with no evidence of granuloma formation, resorption, extrusion or migration of the implant [2,8]. However, adverse responses to Gore-Tex in humans requiring implant removal from the lips, face, nose and larynx have been reported [9-12]. To

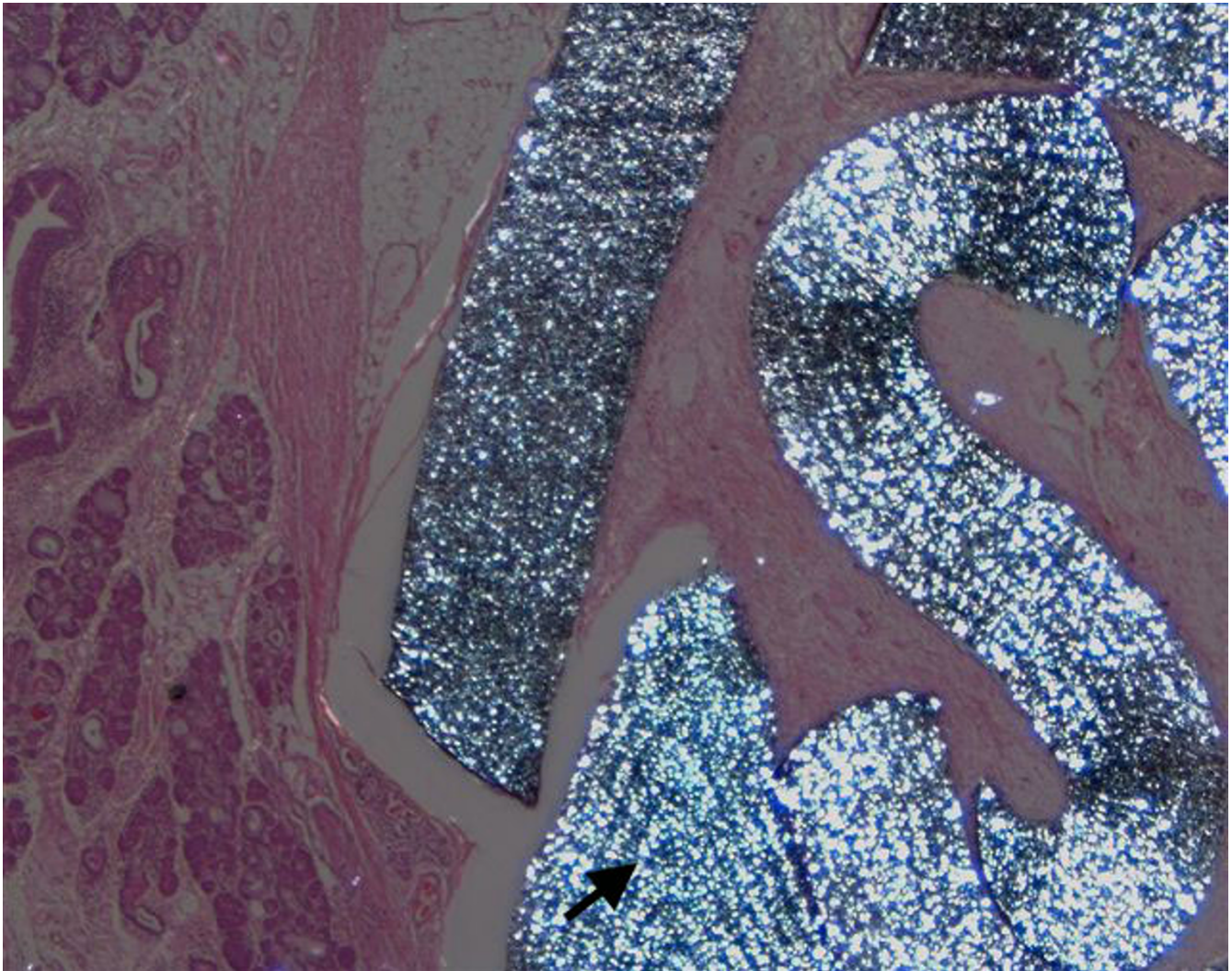


Figure 4
Gore-Tex under crossed polaroids showing birefringence (arrow).

date, there have been no reports describing the histological changes in a human laryngectomy specimen with a Gore-Tex implant.

Conclusions

Our findings are consistent with the animal models confirming that Gore-Tex implantation does not result in a significant granulomatous reaction in the human larynx over a 13-month period. Moreover, there is no evidence of resorption or infection. Further, the lack of lymphocytes in association with the granulomas indicates that there is no significant immunological hypersensitivity. Histologically, the slight permeation by connective tissue is similar to that seen in Gore-Tex vascular and cardiac implants. The degree of the slight giant cell response appears to be

dependent on the profile of the material; a sharp edge incited more of a response than a flat surface.

Competing interests

The author(s) declare that they have no competing interests.

Authors' contributions

All authors equally contributed towards the background research and writing of the paper.

References

1. McCulloch PM, Hoffman HT: **Medialisation laryngoplasty with expanded polytetrafluoroethylene. Surgical technique and preliminary results.** *Annals Otol Rhinol Laryngol* 1998, **107**:427-432.

2. Cashman S, Simpson CB, McGuff HS: **Soft tissue response of the rabbit larynx to Gortex implant.** *Annals Otol Rhinol Laryngol* 2002, **111**:977-982.
3. Varvares MA, Montgomery WW, Hillman RE: **Teflon Granuloma of the larynx: aetiology, pathophysiology and management.** *Annals Otol Rhinol Laryngol* 1995, **104**:511-515.
4. Bauer CA, Valentino J, Hoffman HT: **Longterm results of vocal cord augmentation with autogenous fat.** *Annals Otol Rhinol Laryngol* 1995, **104**:871-874.
5. Stein J, Eliachar I, Munoz-Ramirez H, Myles J, Strom EM: **Histopathologic study of alternative substances for vocal fold medialization.** *Annals Otol Rhinol Laryngol* 2000, **109**:221-226.
6. Giovanni A, Vallicioni J, Gras R, Zanaret M: **Clinical experience with Gore-Tex for vocal fold medialization.** *Laryngoscope* 1999, **109**:284-288.
7. Eisele DW: **Surgical approaches to aspiration.** *Dysphagia* 1991, **6**:71-78.
8. Tamplenizza P, Acocella F, Addis F, Bolandrini E: **Tubular e-PTFE implants in glottal and neoglottal insufficiency: tolerance and stability in an animal model.** *J Laryngol Otol* 2001, **115**(2):106-111.
9. Hubner MG, Hoffman C, Popper H, Scharnagl E: **Expanded polytetrafluoroethylene threads for lip augmentation induce foreign body granulomatous reaction.** *Plast Reconstr Surg* 1999, **103**:1277-1279.
10. Mole B: **The use of Gore-Tex implants in aesthetic surgery of the face.** *Plast Reconstr Surg* 1992, **90**:200-206.
11. Conrad K, Gillman G: **A six year experience with the use of expanded polytetrafluoroethylene in rhinoplasty.** *Plast Reconstr Surg* 1998, **101**:1675-1684.
12. Zeitels SM: **New procedures for paralytic dysphonia: adduction arytenopexy, Gore-Tex medialization laryngoplasty and cricothyroid subluxation.** *Otolaryngol Clin North Am* 2000, **33**:841-854.

Pre-publication history

The pre-publication history for this paper can be accessed here:

<http://www.biomedcentral.com/1472-6815/5/1/prepub>

Publish with **BioMed Central** and every scientist can read your work free of charge

"BioMed Central will be the most significant development for disseminating the results of biomedical research in our lifetime."

Sir Paul Nurse, Cancer Research UK

Your research papers will be:

- available free of charge to the entire biomedical community
- peer reviewed and published immediately upon acceptance
- cited in PubMed and archived on PubMed Central
- yours — you keep the copyright

Submit your manuscript here:
http://www.biomedcentral.com/info/publishing_adv.asp

